

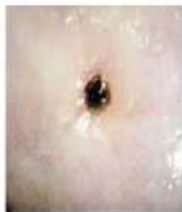## Summary Chart: Identifying Normal and Abnormal Cervical Appearances



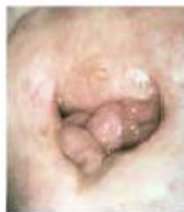### Alberta Cervical Cancer Screening Program

#### Identifying Normal and Abnormal Cervical Appearances

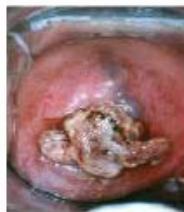Below are examples of cervixes that may be seen during a Pap test. Any visual cervical abnormalities and/or symptoms (i.e. abnormal bleeding or discharge) must be investigated regardless of the Pap test result.



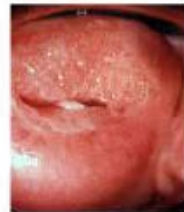Atrophy



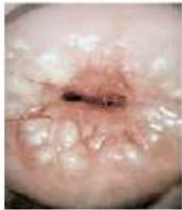Cervical polyps



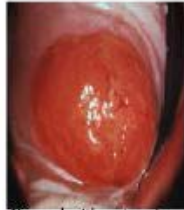Decidual polyp



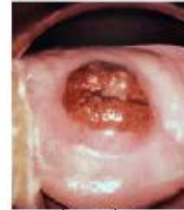
Endocervical polyp



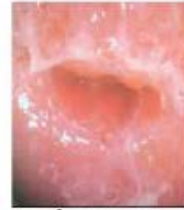Nabothian follicles



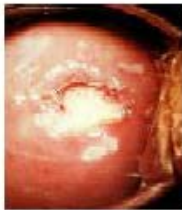Normal with extensive ectropion



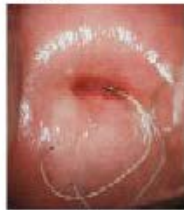Normal, post-laser



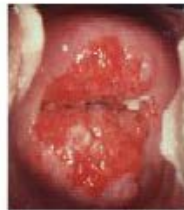Transformation zone



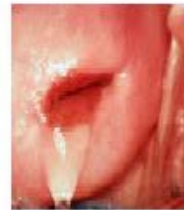Cervical ulcer



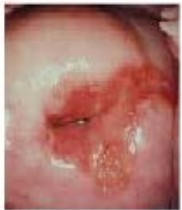Normal with IUCD



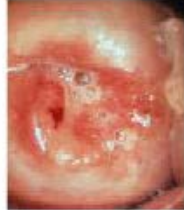Normal with ectropion



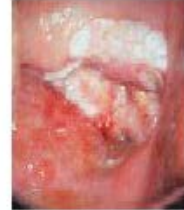Normal



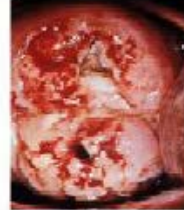Cervical carcinoma



Cervical carcinoma



Cervical carcinoma



Cervical carcinoma

Images taken from:  
 1. Bergant, E. (1995). Colposcopy, Cervical Pathology: Textbook and Atlas, 2nd Ed.  
 2. Leticia, D., K. Pap Test Learning Module: Carcinoma of the Cervix (1989). Accessed at [www.getcheckedmanitoba.ca](http://www.getcheckedmanitoba.ca) on October 16, 2014.

Used with permission from Cervix Check CancerCare Manitoba